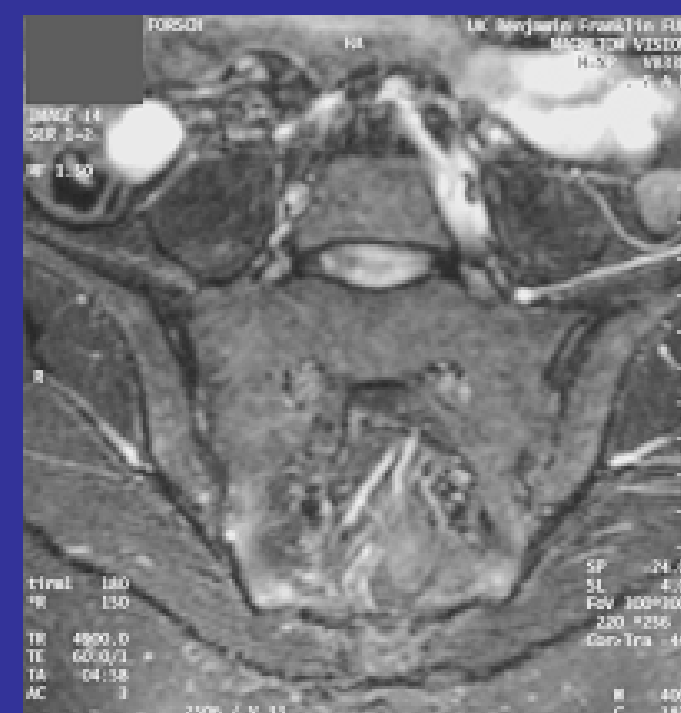
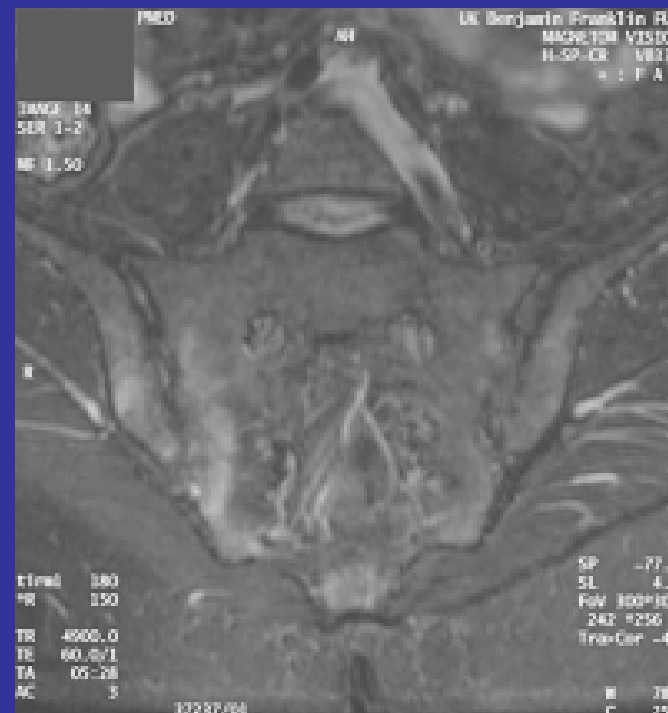
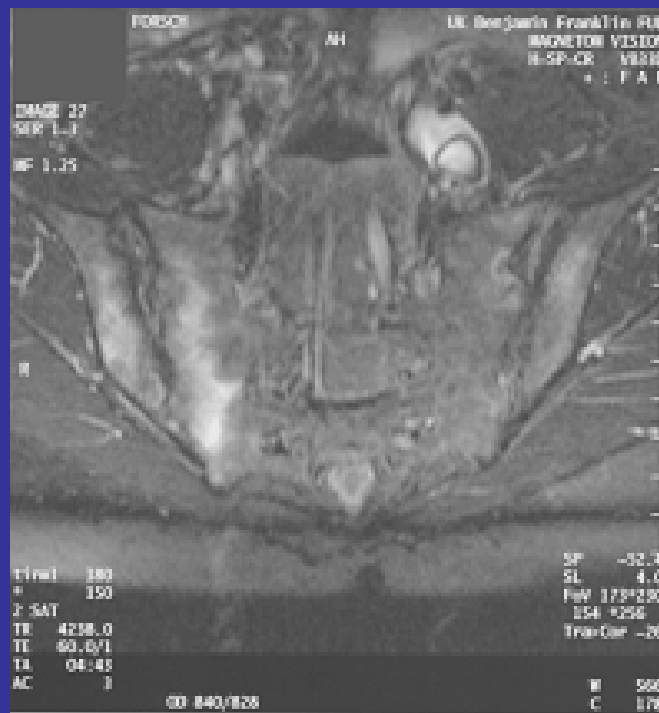

# MRI of Sacroiliac Joints Before and After Etanercept-Treatment

Before

after 6 weeks

after 24 weeks



Rudwaleit et al., Ann Rheum Dis 2005;64:1305-1310

Fig.14