

Compact Bone & Spongy (Cancellous Bone)

Lacunae containing osteocytes

Lamellae

Canaliculi

Osteon

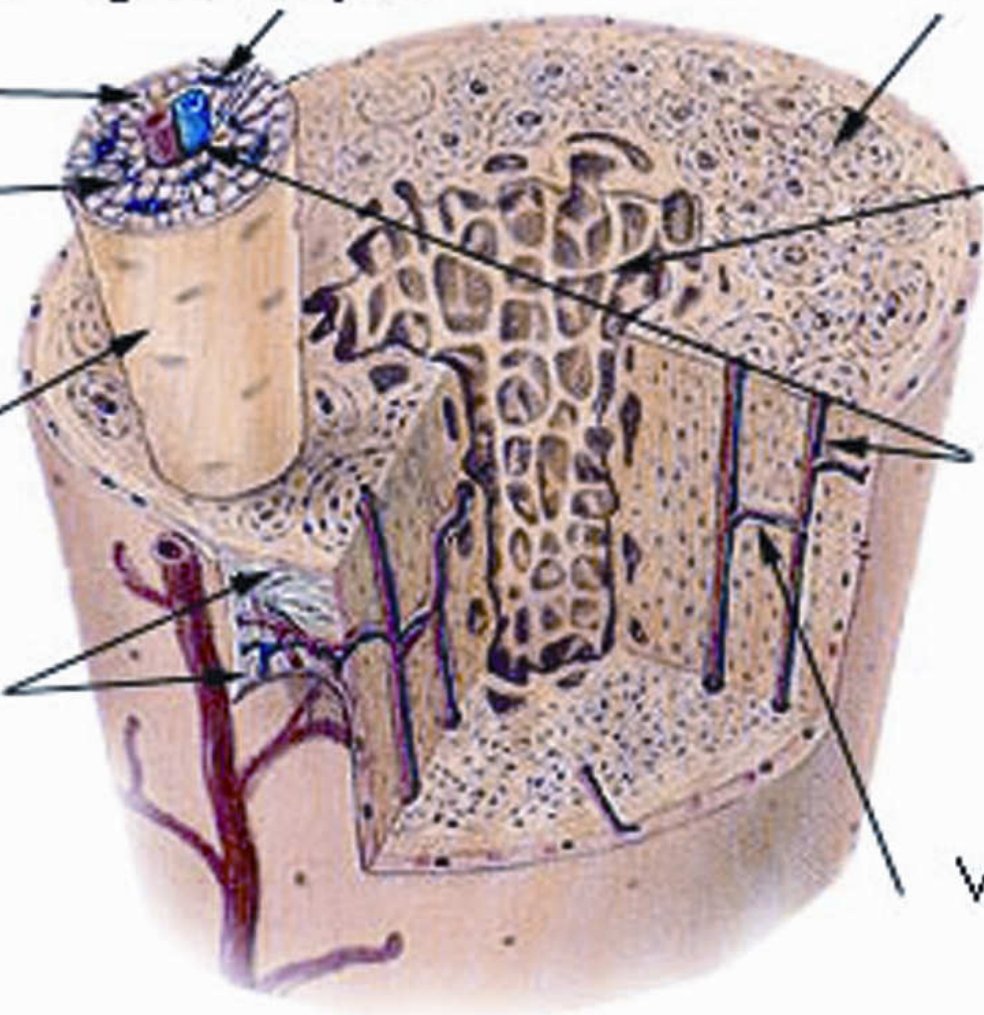
Periosteum

Osteon of compact bone

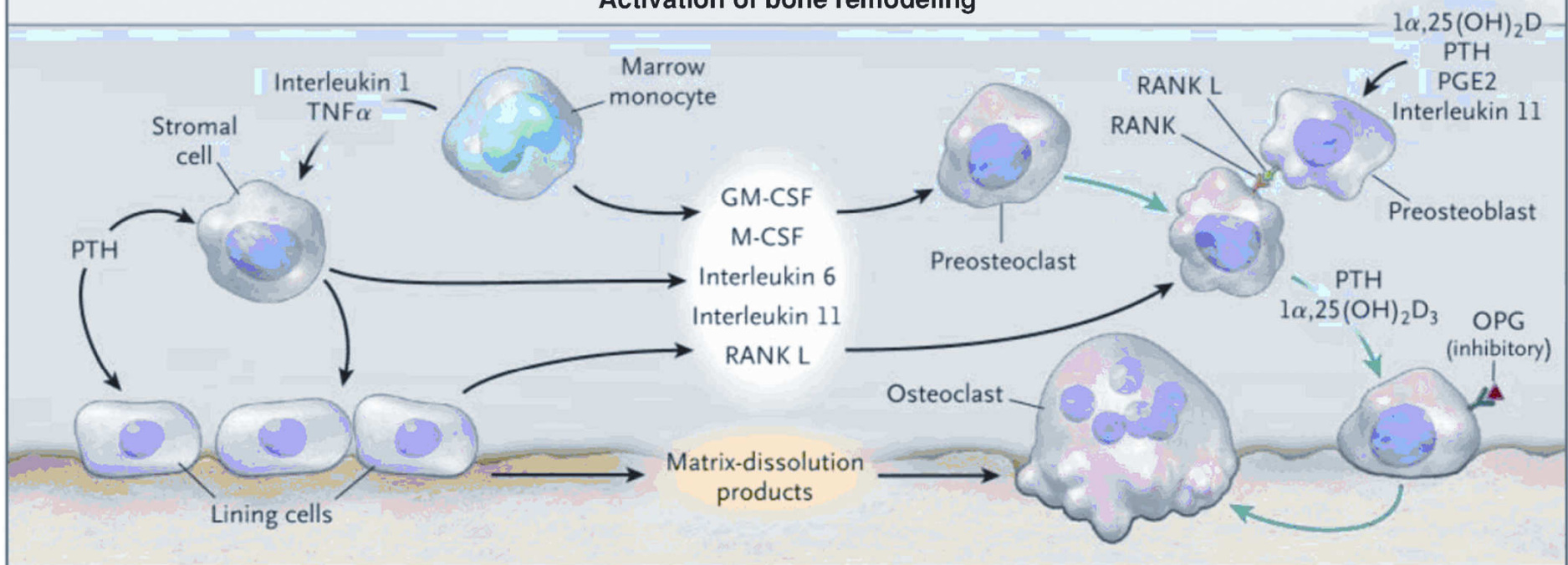
Trabeculae of spongy bone

Haversian canal

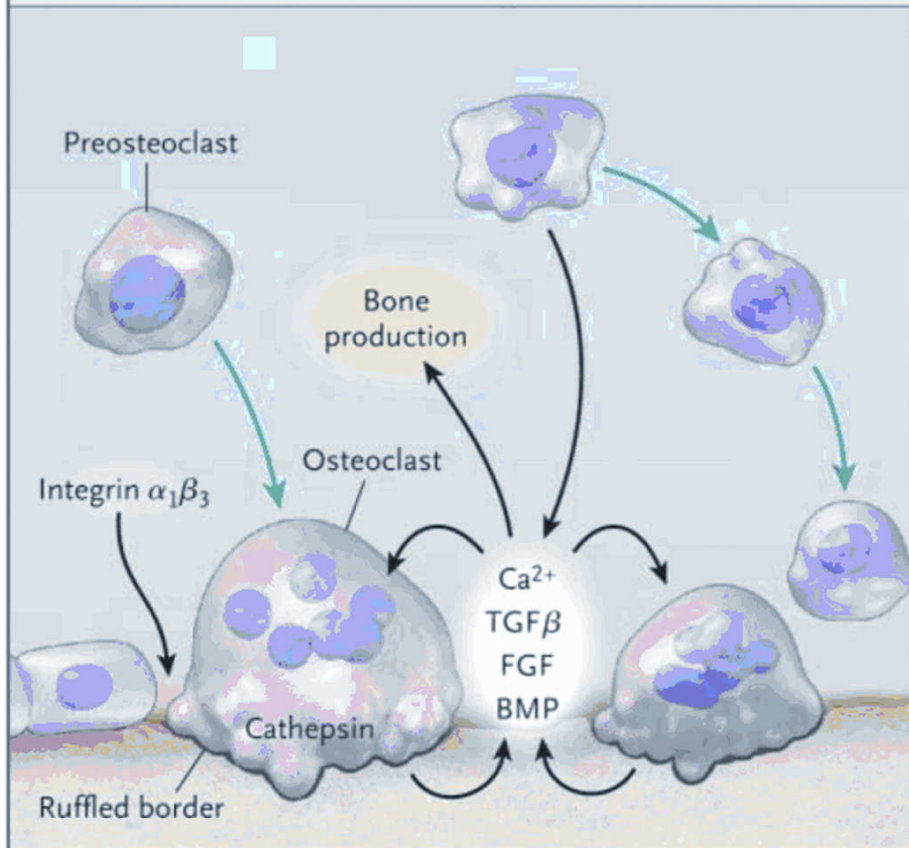
Volkman's canal



Activation of bone remodeling



Bone resorption



Bone formation

